




## ORIGINAL ARTICLE

# Wound repair, safety, and functional outcomes in reconstructive lower extremity foot and ankle surgery using a dehydrated amnion/chorion allograft membrane

Jordan Z. Tackill<sup>1</sup> | Zachary Rasor<sup>2</sup> | Josh Adams<sup>3</sup> | Gary Driver<sup>3</sup> | Logan Shannon<sup>3</sup> | Scott Hudzinski<sup>3</sup> | Marissa J. Carter<sup>4</sup>  | Adam L. Isaac<sup>2</sup>  | Charles M. Zelen<sup>3</sup> 

<sup>1</sup>Kaiser Permanente Mid-Atlantic Division, Largo, Maryland, USA

<sup>2</sup>Foot and Ankle Specialists of the Mid-Atlantic, Salem, Virginia, USA

<sup>3</sup>Professional Education and Research Institute, Roanoke, Virginia, USA

<sup>4</sup>Strategic Solutions, Inc, Bozeman, Montana, USA

## Correspondence

Charles M. Zelen, Professional Education and Research Institute, Inc., 222 Walnut Avenue, Roanoke, VA 24016, USA.  
Email: cmzelen@peridedu.com

## Funding information

Musculoskeletal Transplant Foundation, Grant/Award Number: 008

## Abstract

Amniotic membranes are known to be rich in growth factors, cytokines, and matrix proteins, which can help support wound closure and may improve patient outcomes in foot and ankle surgical interventions. In this Institutional Review Board (IRB) approved clinical study, 21 consecutive patients undergoing lower extremity soft tissue and bone reconstruction surgery received dehydrated human amnion and chorion allograft (dHACA) placed as a covering over the deep layers of the surgical wound during closure. Wound healing complications were assessed and American Orthopaedic Foot and Ankle Society (AOFAS) scores were compiled from over a 1-year follow-up period. Summary statistics were calculated for average pain, function, and alignment. The average overall AOFAS pre-treatment score was  $35.8 \pm 23.0$  and the post-treatment score significantly improved to  $87.5 \pm 6.4$  ( $P = 3.7 \times 10^{-10}$ ). The pain-score improved from pre-treatment at  $10.0 \pm 11.0$  to post-treatment at  $36.7 \pm 4.8$  ( $P = 5.0 \times 10^{-5}$ ). The pre-treatment function score was  $18.7 \pm 12.9$  and at post-treatment increased to  $38.5 \pm 5.7$  ( $P = 5.8 \times 10^{-5}$ ). Lastly, the alignment score at pre-treatment was  $7.1 \pm 4.4$  and at post-treatment was  $12.4 \pm 2.6$  ( $P = .001$ ). These improvements in functional scores were accompanied with clinical observations of reduced surgical complications including a lack of wound dehiscence in the cohort. These clinical findings suggest that the application of aseptically processed dHACA may reduce wound complications and as such may aid in clinical improvements in foot and ankle surgical interventions however a larger comparative trial should be considered to validate these initial findings.

## KEYWORDS

advanced wound matrix, amnion, chorion, reconstruction, wound healing

This is an open access article under the terms of the Creative Commons Attribution-NonCommercial-NoDerivs License, which permits use and distribution in any medium, provided the original work is properly cited, the use is non-commercial and no modifications or adaptations are made.

© 2022 The Authors. *International Wound Journal* published by Medicalhelplines.com Inc (3M) and John Wiley & Sons Ltd.

**Key Messages**

- dHACA placed during surgical closure may help reduce post-operative complications in reconstructive lower extremity foot and ankle surgery
- dHACA placed during surgical closure may participate in improving patient outcomes and decrease pain in reconstructive lower extremity foot and ankle surgery
- amniotic membranes such as dHACA are known to be rich in growth factors, cytokines, and matrix proteins

## 1 | INTRODUCTION

Reconstructive surgery in the foot and ankle presents several unique challenges for post-operative care, and surgical complications can involve infection, dehiscence, necrosis of the incision site, swelling, redness and drainage, as well as severe pain and loss of function.<sup>1</sup> Foot and ankle surgery has been shown to have a higher rate of surgical site infection than other elective orthopaedic procedures with the rate of infection ranging between 0.39% and 4.8%.<sup>1-4</sup> Thus, when considering the types of procedures utilised in reconstructive surgery of the foot and ankle, such as osteotomies, fusions, and arthroplasty, along with extensive soft tissue dissection and bone resection, post-operative complications may be unavoidable.

In fact, for surgeries involving the ankle, it has been shown that in patients with ankle fractures undergoing open reduction internal fixation (ORIF), 5.1% experienced a complication,<sup>5</sup> while a 15.4% complication rate was noted in patients undergoing total ankle arthroplasty (TAA).<sup>6</sup> Such complications include wound dehiscence, infection, delayed healing, and loss of function. Furthermore, post-operative pain is higher in orthopaedic type of procedures, including the lower extremity, than any other type of surgery.<sup>7-8</sup> Poorly controlled post-operative pain can lead to adverse events such as increased length of hospitalisation, prolonged recovery, and overall patient dissatisfaction.<sup>9</sup> And, given the weight bearing restrictions often necessary for successful outcomes, limitations on a patient's mobility can result in an increased risk for thromboembolism.<sup>9</sup> Therefore, a need exists to identify and evaluate innovative ways to decrease the rate of complications in reconstructive foot and ankle surgery, and optimise functional and timely recovery.

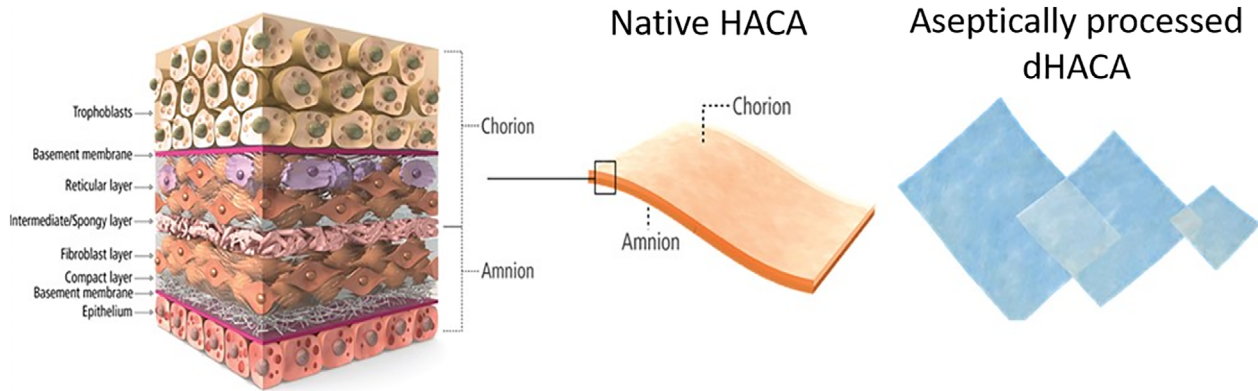
Amnion and chorion membranes from human placenta have been used for over a century in the clinical setting. Their efficacy is due simply to their natural role as a barrier with restorative properties. The membranes are rich in growth factors, cytokines, and matrix proteins.<sup>10,11</sup> From literature, these components are known to reduce inflammation, support cell function and facilitate neovascularization.<sup>10-14</sup> These intrinsic characteristics of amniotic membranes make them a feasible option to support wound closure. Over the last decade these

grafts have become a mainstay for the closure of diabetic wounds. There is substantial research performed on a multitude of different amniotic grafts that are currently available that highlight the success over prior therapies as well as standard of care.<sup>15-20</sup> In addition to research in wound closure, amnion, and chorion have also showed promise in addressing pathology in orthopaedic applications. Only a few small trials and case series have been published highlighting their success.<sup>21-25</sup> Thus, there is a paucity of literature that has been published correlating the application of the grafts with functional rehabilitation in reconstructive foot and ankle surgical patients.

Dehydrated human amnion and chorion allograft (dHACA), Salera Allograft Placental Membrane, MTF Biologics, Edison, New Jersey) is an aseptically processed amnion and chorion tissue form (Figure 1) for use as a protective covering as a Human Cellular and Tissue-Based Product (HCT/P) under FDA 21 CFR 1271 and Section 361 of the Public Health Service (PHS) Act. The proprietary method for aseptically procuring and processing dHACA is designed to retain as much of the native state of these complex tissues through simple treatment steps and by avoiding irradiation sterilisation while the preservation technique renders it shelf stable at ambient temperature for up to 3 years.

In this trial, dHACA was used in a series of surgical cases and applied directly over the deep layers of the surgical wound at the time of closure, with a goal to support the healing process and assess the functional capacity. While previous studies have measured the ability of the amniotic matrices to accelerate wound closure, no studies have addressed the functional capabilities of patients following dHACA implantation in a variety of reconstructive foot and ankle surgery procedures. To calculate a measurable functional outcome, the American Orthopaedic Foot and Ankle Society (AOFAS) clinical scoring system was used. Originally developed in 1994, the AOFAS clinical rating systems for ankle-hind-foot, mid-foot, hallux, and lesser toes have emerged as one of the most commonly used tools for evaluating treatment outcomes in foot and ankle surgery.<sup>26,27</sup>

The authors have conducted a retrospective Institutional Review Board (IRB) approved clinical study to analyse results calculated from patients who have undergone



**FIGURE 1** Schematic of native human amnion and chorion allograft (HACA) structure and aseptically processed without terminal sterilisation dHACA that is sourced from donated human birth tissue, and processed by MTF Biologics

reconstructive foot and ankle surgery with implantation of an amnion/chorion allograft membrane.

## 2 | MATERIALS AND METHODS

This study was reviewed and approved under Western Institutional Review Board (WIRB #20201284). Around 21 sequential surgical patients were selected that were undergoing foot and ankle surgery. They varied in age (24-76 years old) and comorbidities. Each patient underwent open surgery of the lower extremity with bone and soft tissue reconstructive procedures. dHACA was applied using standard technique without prior moisturization of the graft as the graft was rehydrated with the body's own fluid.

The graft was cut to the size of the surgical wound and placed during the deep portion of closure, superficial to the periosteal and capsular tissues during closure of the surgical wound. The procedures performed included ankle arthrodesis, ankle arthroplasty, pilon fractures open reduction with internal fixation, ankle fracture open reduction with internal fixation, rear-foot arthrodesis, mid-foot arthrodesis, Lisfranc open reduction with internal fixation, first metatarsal phalangeal joint arthrodesis, extensor hallucis longus repair, first metatarsal closing wedge osteotomy, and first metatarsal phalangeal joint cheilectomy. All midfoot, rearfoot, and ankle surgeries were offloaded during the initial 4 to 6 weeks after surgery with a cast or surgical boot. In all the fore-foot surgeries, the patients were weight bearing with a surgical shoe. Patients were seen for standard follow-up and consented with an approved WIRB consent prior to collecting any patient specific information.

Summary statistics (means and standard deviation [SD]) were calculated for all variables of interest. AOFAS scores were compiled from patients over a 1 year follow up period. The AOFAS scores are subdivided into ankle-hindfoot, midfoot, and forefoot (hallux, metatarsalphalangeal-interphalangeal) groups, and differ in terms of total calculated

score. For example, the maximum ankle-hindfoot alignment score is 10, whereas the midfoot and forefoot alignment scores are graded up to 15. For the change in overall AOFAS score between pre-and post-treatments, a paired *t*-test was used; for changes in pain, function, and alignment, between pre- and post-treatment the Wilcoxon signed rank test was used. Statistical analysis used PASW27 with alpha set to 0.05.

## 3 | RESULTS

There were 21 patients where 11 (52%) were in the hind-foot-ankle AOFAS subgroup, 8 (38%) were in the mid-foot AOFAS subgroup, and 2 (10%) were in the hallux AOFAS subgroup.

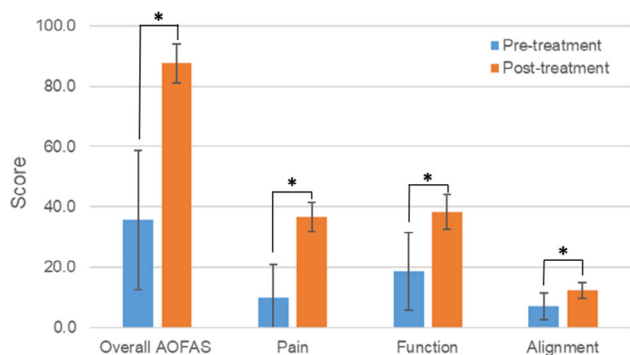
The average overall AOFAS pre-treatment score was  $35.8 \pm 23.0$  and post-treatment was at  $87.5 \pm 6.4$  ( $P = 3.7 \times 10^{-10}$ ). The pain score improved significantly from pre-treatment at  $10.0 \pm 11.0$  to post-treatment at  $36.7 \pm 4.8$  ( $P = 5.0 \times 10^{-5}$ ), where 40 indicates no pain (92% pain free level). The pre-treatment function score was  $18.7 \pm 12.9$  and at post-treatment was at  $38.5 \pm 5.7$  ( $P = 5.8 \times 10^{-5}$ ) out of 50 (77% full function level). Lastly, the alignment score was  $7.1 \pm 4.4$  at pre-treatment and was  $12.4 \pm 2.6$  at post-treatment ( $P = .001$ ) (Figure 2).

Some representative cases are summarised below to illustrate the application of and resulting observations of adding dHACA in open surgeries of the lower extremity with bone and soft tissue reconstructive procedures.

### 3.1 | Case 1: Reconstructive midfoot surgery

This is a case of 76 year old female with a long history of congenital foot deformity, obesity, and had 40 year history of rheumatoid arthritis (Figure 3A,B). She has

walked with pain for over four decades and was unable to accommodate her deformity in normal shoe gear. The patient did attempt custom shoe gear with orthotics and then bracing but continued to have pain with ambulation. The treatment recreated her arch with plates and hardware. Two osteotomies were designed encompassing the deformity to achieve correction. The first osteotomy was oriented perpendicular to the long axis of the fore-foot and the second osteotomy oriented perpendicular to the long axis of the rear-foot forming a wedge. As the osteotomies were completed the central portion of bone was removed and a closing wedge was fixated with screw and plate fixation (Figure 3C,D). These areas are difficult to heal as not much

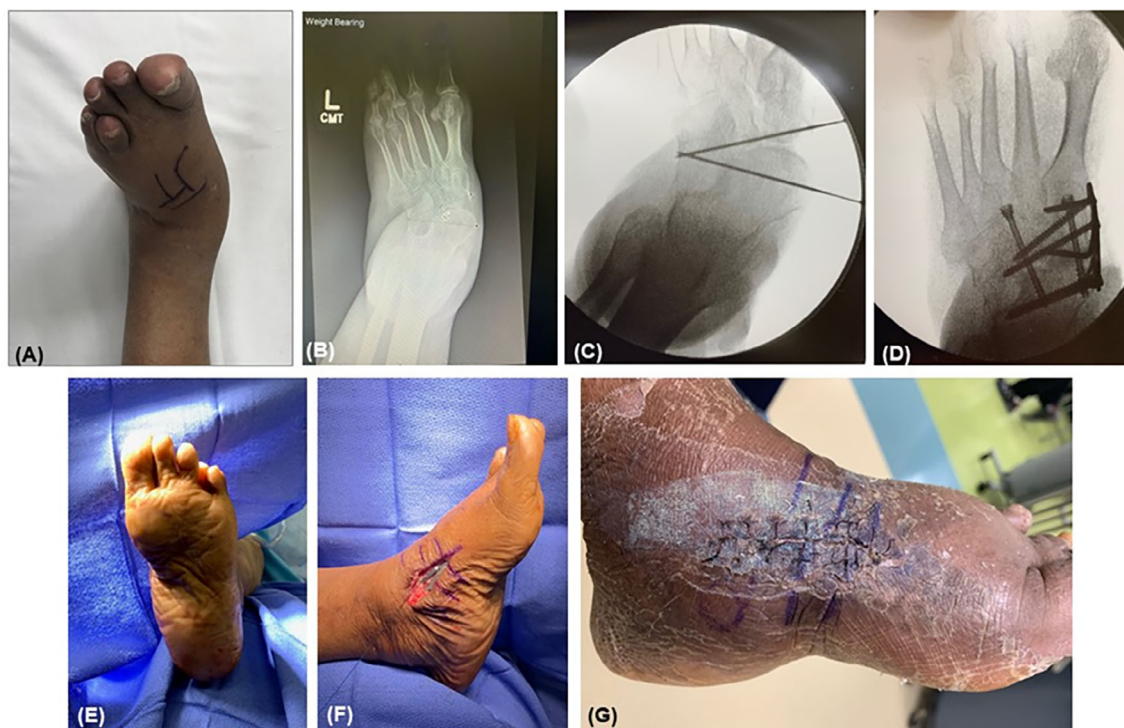


**FIGURE 2** Overall AOFAS scores significantly improved at 1 year post-treatment along with AOFAS pain, function and alignment scores (\*statistically significant  $P < .05$ )

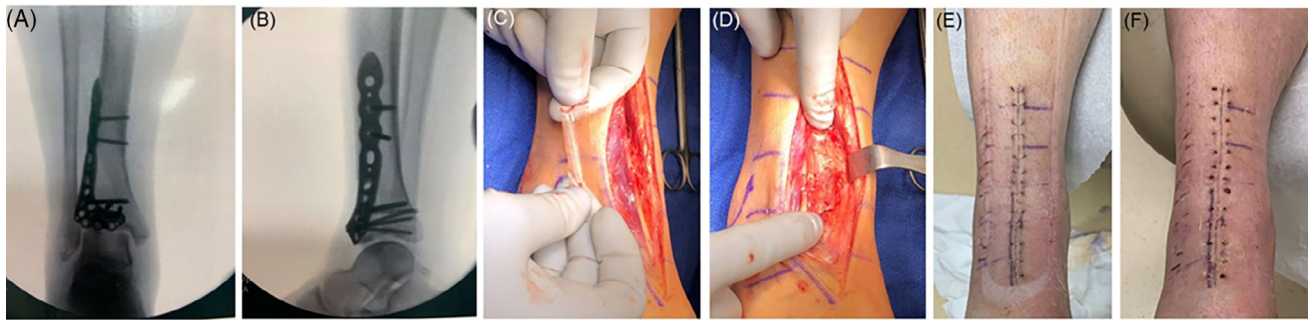
soft tissue is present between the arch plate and the tissue in that location. As the exposed bone over the dorsal medial foot incision was fixated and closure was initiated with the periosteum, the dHACA was applied directly to the periosteal layer followed by the subcutaneous closure and skin closure (Figure 3E,F). The dressings placed around the incisional site included Xeroform,  $4 \times 4$ 's, Kerlix, cast padding, and Coban. Following completion of the dressing, a posterior splint was applied with the foot placed in 90-degree orientation to the leg and the patient was advised to remain non-weight bearing to the operative limb. In this location, there is typically a large amount of swelling and redness observed at the incision site post-surgery due to inflammation. With the addition of dHACA, it was observed in the patient that there was only a small amount of swelling and redness at day 3, leading to a healed incision site by 2 weeks (Figure 4G). This may suggest a benefit of adding dHACA to the treatment arsenal. The patient was able to resume her normal life activities and started wearing regular athletic shoes and walked regularly which she was not able to without pain for much of her life.

### 3.2 | Case 2: Ankle trauma

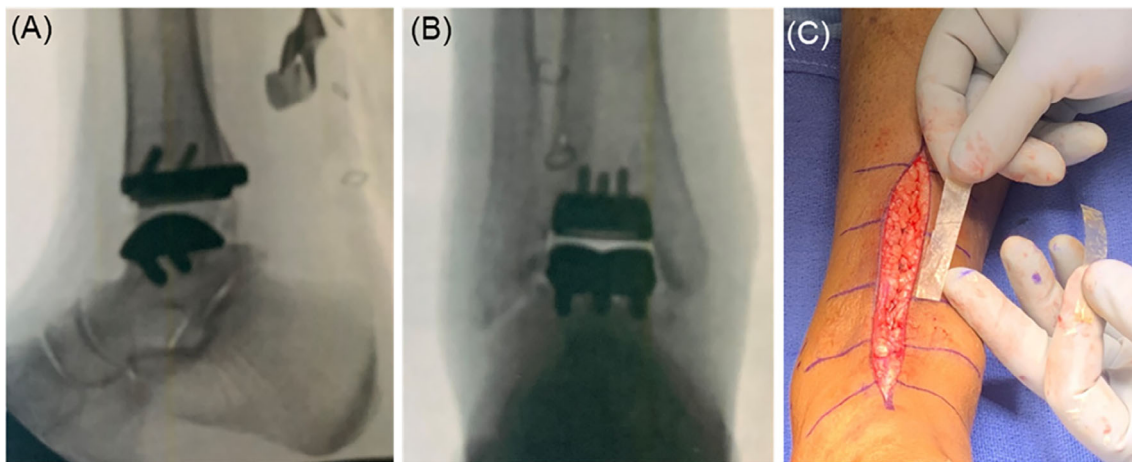
This case is of a 41 year old male with a history of a severe pilon fracture after a fall in the down stairs. The fracture on CT was a comminuted intra-articular distal



**FIGURE 3** Midfoot example. (A and B) Congenital foot deformity, (C and D) Recreated arch with plates and hardware, (E and F) Intraop images with amnion graft placement and closing the wound, and (G) 2 weeks post-op, the incision site is closed



**FIGURE 4** Ankle trauma example (A and B) Anterior Posterior and Lateral radiographic projection of pilon fracture following open reduction with internal fixation; (C and D) Clinical photograph of the pilon fracture anterior ankle incision with application of dHACA about the periosteal and capsular structures during deep closure of the incision site; (E) Wound had minimal edema and erythema at 1 week and (F) Wound healed with no complications (no dehiscence) at 3 weeks

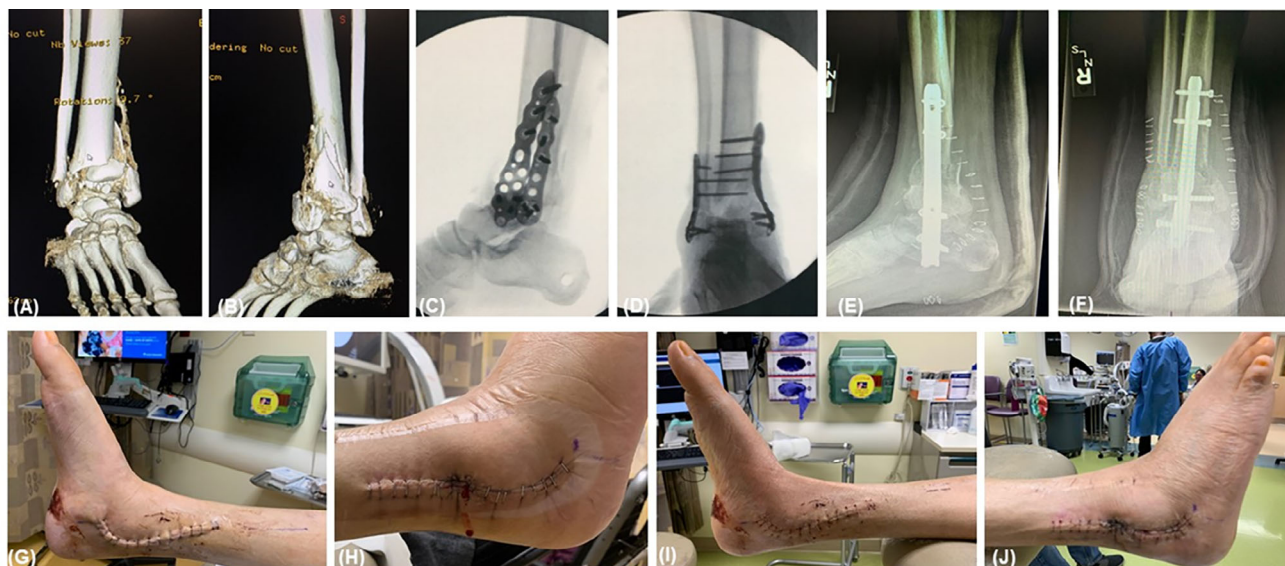

**FIGURE 5** (A) Lateral X-Ray of total ankle replacement, (B) AP X-Ray of total ankle replacement, (C) Clinical photograph of the anterior ankle incision with application of dHACA about the anterior extensor retinaculum during deep closure of the incision site

tibial fracture with fracture lines extending into the tibiotalar joint and anterior syndesmosis. There was a depressed fracture fragment with 4 mm of cortical step-off at the ankle mortise. The patient underwent ORIF with locking plate and screws with near anatomic reduction (Figure 4A,B) and placement of dHACA on the anterior surgical wound directly over the periosteum prior to deep closure (Figure 4C,D). The dressings placed around the incisional site included Xeroform, 4 × 4's, Kerlix, cast padding, and Coban. Following completion of the dressing, a posterior splint was applied with the foot placed in 90-degree orientation to the leg and the patient was advised to remain non-weight bearing to the operative limb for 8 weeks. The surgical site healed with no complications observed and with minimal edema and erythema despite the very high risk of surgical dehiscence in this type of trauma (Figure 4E,F). The patient progressed back to ambulation at week 8 and back to regular activity at week 12.

### 3.3 | Case 3: Ankle arthroplasty

This is about a 53 year old obese female and former smoker with right ankle pain and progressive osteoarthritis for 19 years. She also suffers from osteoarthritis, asthma, diabetes under good control, fibromyalgia, and Gastroesophageal reflux disease (GERD). She took steroids for her respiratory condition. The patient measured her pain at 10/10. Patient had been treated with both over the counter and with a custom Arizona Brace. She has had prior steroid injections into the right ankle which did not help her. She also got to the point where she needed to use a Controlled Ankle Motion (CAM) boot for ambulation as the pain had gotten so bad. She underwent total ankle arthroplasty with placement of dHACA over the periosteum prior to closure (Figure 5A-C). Total ankle arthroplasties are known to have a very high wound complication rate. However, this patient healed her wound without incident despite her significant co-morbidities.



**FIGURE 6** Ankle (Pilon fracture/ankle trauma) case. (A and B) crushed distal tibia; (C-F) Hardware and bone was removed and filled with a femoral head and an intermedullary nail supplemented with external fixator; (G-J) very little swelling was observed as opposed to a significant amount of swelling, at time of external fixator removal, incision site healed very well with no dehiscence (typically with these procedures, there is significantly high dehiscence rate observed). Patient went on to weight bearing with no pain

### 3.4 | Case 4: Pilon fracture/ankle

The final case is of a 56 year old male, a patient with diabetes, and a history of poor control who sustained a crushed distal tibia (Figure 6A,B). The treatment involved removing the unhealed bone and using an inter-positional femoral head with intramedullary (IM) nail and an external fixator (Figure 6C-F). This procedure typically results in a tremendous amount of swelling and tension on skin and bone due to the extensive dissection and removal of dead bone and placement of allograft. Thus, this procedure has an extremely high dehiscence rate. The dHACA was placed over the periosteum prior to closure. Post-surgery, the observations were reduced swelling, inflammation, and pain experienced by the patient. At the incision site, lack of swelling was observed. There was no dehiscence observed (Figure 6G-J) and the pain level decreased (attributed to less inflammation/swelling). The duration of pain medication also reduced as a consequence. Typically, patients request pain medication for many weeks post-surgery, sometimes as long as 6 to 8 weeks. In this case, the use of narcotics was curtailed to around 5 to 7 days and after which was reduced to Tylenol. The ankle joint area has healed well and the patient has resumed normal weight bearing activities with solid fusion.

## 4 | DISCUSSION

Common post-operative complications from reconstructive surgery of the foot and ankle include pain at the

surgical site, infection, wound necrosis, dehiscence, and prolonged swelling, redness, and/or drainage. Compared with other types of surgery, orthopaedic procedures have a higher incidence of pain.<sup>7</sup> In the foot and ankle, one study found that the majority of patients reported high pain during the early post-operative periods with the most severe pain occurring 3 days after surgery. However, by 6 weeks most patients experienced only a small amount of pain.<sup>8</sup> Similar results were observed in a study looking at patients undergoing ORIF for acute ankle fractures, in which pain levels were highest preoperatively and in the early post-operative period with a marked decrease by 6 weeks.<sup>28</sup>

In another prospective study conducted by Wiewiorski and colleagues,<sup>1</sup> the authors evaluated the rate of wound complications in patients undergoing elective foot and ankle surgery and analysed the risk factors associated with post-operative wound complications in these cases. Included in the study were 295 elective orthopaedic foot and ankle operative procedures performed in 290 patients between January 2006 and June 2010. The primary procedures performed included hammer toe correction, first metatarsophalangeal joint arthrodesis, Lisfranc arthrodesis, Triple arthrodesis, total ankle replacement, and ankle arthrodesis. Results demonstrated an overall post-operative wound complication rate of 16.9% with age at the time of surgery, tobacco use, and prolonged use of a tourniquet representing independent risk factors for complications.<sup>1</sup>

Belmont and coworkers<sup>5</sup> assessed the incidence of post-operative mortality, complications, and length of

hospital stay in patients with acute ankle fractures requiring ORIF. The authors utilised data taken from the National Surgical Quality Improvement Program (NSQIP) and found that among 3328 patients undergoing ORIF between 2006 and 2011, 229 complications were noted among 170 patients in the initial 30 days following surgery. Major complications included sepsis and pulmonary embolism, and superficial wound infection as well wound dehiscence were the most common minor local complications observed. The authors also noted that the risk factors for post-operative complications in this cohort included peripheral vascular disease, an open or contaminated/dirty wound, age 70 years or older, and American Society of Anesthesiologists (ASA) classification greater than or equal to 3.<sup>5</sup>

A retrospective analysis conducted by Borenstein, et al,<sup>6</sup> the authors investigated 65 consecutive patients undergoing outpatient total ankle arthroplasty (TAA) between 2012 and 2016, with a minimum follow-up period of 6 months, and reported an overall complication rate of 15.4%. One patient with a history of polycythemia vera (PV) complicated by re-thrombosis of an ipsilateral popliteal artery required debridement with flap coverage, secondary to a wound complication (surgical site dehiscence/necrosis), and the rate of infection requiring irrigation and debridement in the post-operative periods was 1.5%.<sup>6</sup> A more recent analysis of over 1300 patients undergoing foot and ankle surgery in an ambulatory setting over a 5-year period (2010-2015) found an overall infection rate of 1.7%. Of note, nearly half of infection cases (48%) involved patients with a history of diabetes.<sup>9</sup>

Amniotic allograft matrices have made their mark with advantageous increases in wound healing when applied to chronic ulcerations.<sup>15-20</sup> Further review of over 6780 articles completed by Riboh et al to decipher the possible sports medicine applications and the beneficial science that contributes to the positive outcomes of patients concluded the intrinsic properties of amniotic membranes support the wound-healing process, reduce inflammation, reduce scar formation and pain at the application site, along with providing a matrix for cellular migration and proliferation.<sup>29</sup> Dolivo et al<sup>30</sup> performed studies on diabetic mice and reported that the application of dHACA enhanced the rate of wound closure compared with a control (no tissue applied) with more granulation tissue deposited and closure of the epithelial gap. Furthermore, there was more vascularization observed in the wound bed that would help more granulation tissue to be formed to support wound closure. More importantly, there was a shift in macrophage polarisation towards an anti-inflammatory phenotype earlier in the wound healing process. And lastly, Dolivo et al reported a suppression of the pro-fibrotic processes from genomic

analysis.<sup>30</sup> The findings and observations in these clinical studies with Amnion may indicate why we have observed similar findings of less inflammation, swelling, and pain, in our cohort of patients. It is important to note though that a larger robust randomised trial with a comparative arm would be needed to validate these initial observations. Such large randomised controlled trials have been done in diabetic wound healing. Human studies have shown that the application of aseptically processed dHACA in randomised controlled trials treating Diabetic Foot Ulcers (DFUs) resulted in 85% wound closure compared to 33% with standard of care (SOC).<sup>19</sup>

The goal of this retrospective study was to examine how dHACA could support reconstructive foot and ankle surgery and examine functional outcomes. Around 21 consecutive patients with varying co-morbidities underwent open surgery with soft tissue and bone reconstruction along the fore-foot, mid-foot and hind-foot/ankle. AOFAS scores are well established in the orthopaedic literature as a validated method for evaluating post-operative function and success of the procedures.<sup>31</sup> The overall AOFAS scoring along with the sub-groups of pain, function and alignment, statistically significantly improved from pre-treatment to post-treatment. Furthermore, clinical observations revealed decreased inflammation and swelling, no wound dehiscence and decreased pain. This all translated to improved patient function: patients were experiencing less pain and taking less pain medication, they were starting to walk earlier than we would normally expect and resuming work and normal activities in a shorter time frame as well. Therefore, the overall quality of life for the patients returned at a faster rate. In this study dHACA was applied over the reconstruction in each of these patients, and may have played a role in the improved clinical observations based on the science behind the nature of the amniotic membrane and its effect on soft tissues. Other studies have showed similar findings such as, DeMill et al, applied a cryopreserved amniotic membrane to Achilles tendon repair surgical patients, and found an overall decrease in post-operative complication and revision rates.<sup>24</sup> Warner et al hypothesized complex foot and ankle surgery using amniotic membrane would be an effective treatment leading to reduced pain and improved functional outcomes. A total of 14 patients (6 male and 8 female) underwent open foot and ankle surgery during the study period. All the patients reported improvement with less pain intensity both on the AOFAS scale and the pain numeric rating scale (NRS), as well as improved functional status.<sup>25</sup> But, to clearly prove out and validate these findings more studies looking at amnion/chorion grafting as a part of orthopaedic surgical closure should be considered with the additional rigour of a large

number of patients, randomization and a control group so the study can be powered to show a statistical difference in the two groups.

The strength of our trial includes a single surgeon performing all procedures and closure for consistency of the patient population, the complexity of the surgeries performed and the rigorous statistical analysis. Limitation of the study is the retrospective nature of the trial, lack of a control arm to isolate the distinct benefits associated with dHACA, and the relatively small sample size of patients. Furthermore, because the AOFAS scores are subdivided by anatomical location, and vary by total score, we are thus limited as to our conclusions when attempting to compare the different surgical procedures. However, comparison of the pre-, and post-treatment scores within the same anatomical subgroup are consistent throughout. Future studies should be considered choosing specific foot and ankle indications with Level 1 evidence to further strengthen and validate the results gathered in this study.

## 5 | CONCLUSION

This study suggests that usage of dHACA in foot and ankle surgery may be advantageous to supporting wound healing and reducing wound complications while aiding function post-surgery. In this case series where dHACA was applied prior to subcutaneous and skin closure, patients going through foot and ankle surgery significantly improved functional scores accompanied with clinical observations of decreased swelling and inflammation, pain, no wound dehiscence, and faster return to activities. Further studies should be considered to validate the potential additive benefits of amnion/chorion allografts suggested in our study.

### ACKNOWLEDGEMENTS

This study was funded through a research grant from Musculoskeletal Transplant Foundation (MTF Biologics); provided to the Professional Education and Research Institute (PERI), which Charles M. Zelen, DPM is medical director.

### CONFLICT OF INTEREST


Jordan Z. Tacktil, DPM; has no conflict of interest to report. Zachary Rasor DPM; has no conflict of interest to report. Josh Adams DPM; has no conflict of interest to report. Gary Driver, DPM; has no conflict of interest to report. Logan Shannon DPM; has no conflict of interest to report. Scott Hudzinski DPM has no conflict of interest to report. Marissa J. Carter, PhD received research funds to provide the statistical analysis plan,

and provide the statistical analysis for this trial and assist with writing of the result section of the manuscript. Adam L. Isaac, DPM has no conflict of interest to report. Charles M. Zelen, DPM is the medical director of the PERI and PERI received research funds to administrate the clinical trial and write the paper for publication. There are no other conflict of interests with any of the authors in relationship to this study or with regard to MTF Biologics. IRB conflict of interest statements are on file with PERI.

### DATA AVAILABILITY STATEMENT

The data that support the findings of this study are available from the corresponding author upon reasonable request.

### ORCID

Marissa J. Carter  <https://orcid.org/0000-0002-2265-6639>

Adam L. Isaac  <https://orcid.org/0000-0001-5338-3445>

Charles M. Zelen  <https://orcid.org/0000-0001-5682-7056>

### REFERENCES

1. Wiewiorski M, Barg A, Hoerterer H, Voellmy T, Henninger HB, Valderrabano V. Risk factors for wound complications in patients after elective orthopedic foot and ankle surgery. *Foot Ankle Int.* 2015;36(5):479-487.
2. Ralte P, Molloy A, Simmons D, Butcher C. The effect of strict infection control policies on the rate of infection after elective foot and ankle surgery: a review of 1737 cases. *Bone Joint J.* 2015;97(4):516-519.
3. Wukich DK, Lowery NJ, McMillen RL, Frykberg RG. Postoperative infection rates in foot and ankle surgery: a comparison of patients with and without diabetes mellitus. *JBJS.* 2010;92(2):287-295.
4. Miller WA. Postoperative wound infection in foot and ankle surgery. *Foot Ankle.* 1983;4(2):102-104.
5. Belmont PJ Jr, Davey S, Rensing N, Bader JO, Waterman BR, Orr JD. Patient-based and surgical risk factors for 30-day postoperative complications and mortality after ankle fracture fixation. *J Orthop Trauma.* 2015;29(12):e476-e482.
6. Borenstein TR, Anand K, Li Q, Charlton TP, Thordarson DB. A review of perioperative complications of outpatient total ankle arthroplasty. *Foot Ankle Int.* 2018;39(2):143-148.
7. Chung F, Ritchie E, Su J. Postoperative pain in ambulatory surgery. *Anesth Analg.* 1997;85(4):808-816.
8. Chou LB, Wagner D, Witten DM, et al. Postoperative pain following foot and ankle surgery: a prospective study. *Foot Ankle Int.* 2008;29(11):1063-1068.
9. Adamson P, Peters W, Janney C, Panchbhavi V. The safety of foot and ankle procedures at an ambulatory surgery center. *J Orthop.* 2020;1(21):203-206.
10. Stern M. The grafting of preserved amniotic membrane to burned and ulcerated surfaces, substituting skin grafts: a preliminary report. *JAMA.* 1913;60(13):973-974.



11. Niknejad H, Peirovi H, Jorjani M, Ahmadiani A, Ghanavi J, Seifalian AM. Properties of the amniotic membrane for potential use in tissue engineering. *Eur Cell Mater*. 2008;15:88-99.
12. Ilancheran S, Moodley Y, Manuelpillai U. Human fetal membranes: a source of stem cells for tissue regeneration and repair? *Placenta*. 2009;30(1):2-10.
13. Steed DL, Trumpower C, Duffy D, et al. Amnion-derived cellular cytokine solution: a physiological combination of cytokines for wound healing. *Eplasty*. 2008;8:e18.
14. Mamede AC, Carvalho MJ, Abrantes AM, Laranjo M, Maia CJ, Botelho MF. Amniotic membrane: from structure and functions to clinical applications. *Cell Tissue Res*. 2012;349:447-458.
15. Zelen CM. An evaluation of dehydrated human amniotic membrane allografts in patients with DFUs. *J Wound Care*. 2013;22(7):347-348, 350-351.
16. Zelen CM, Serena TE, Denozieri G, Fetterolf DE. A prospective randomised comparative parallel study of amniotic membrane wound graft in the management of diabetic foot ulcers. *Int Wound J*. 2013;10(5):502-507.
17. Zelen CM, Serena TE, Snyder RJ. A prospective, randomised comparative study of weekly versus biweekly application of dehydrated human amnion/chorion membrane allograft in the management of diabetic foot ulcers. *Int Wound J*. 2014;11(2):122-128. 45.
18. Zelen CM, Snyder RJ, Serena TE, Li WW. The use of human amnion/chorion membrane in the clinical setting for lower extremity repair: a review. *Clin Podiatr Med Surg*. 2015;32(1):135-146.
19. DiDomenico LA, Orgill DP, Galiano RD, et al. Aseptically processed placental membrane improves healing of diabetic foot ulcerations: prospective, randomized clinical trial. *Plast Reconstr Surg Glob Open*. 2016;4:e1095.
20. Lavery LA, Fulmer J, Shebetka KA, et al. The efficacy and safety of Grafix<sup>®</sup> for the treatment of chronic diabetic foot ulcers: results of a multi-centre, controlled, randomised, blinded, clinical trial. *Int Wound J*. 2014;11:554-560.
21. Zelen CM, Poka A, Andrews J. Prospective, randomized, blinded, comparative study of injectable micronized dehydrated amniotic/chorionic membrane allograft for plantar fasciitis: a feasibility study. *Foot Ankle Int*. 2013;34(10):1332-1339. 47.
22. Hanselman AE, Tidwell JE, Santrock RD. Cryopreserved human amniotic membrane injection for plantar fasciitis: a randomized, controlled, double-blind pilot study. *Foot Ankle Int*. 2015;36(2):151-158. 48.
23. Jay RM. Initial clinical experience with the use of human amniotic membrane tissue during repair of posterior tibial and achilles tendons. 2009. <http://encompassbiologics.com/content/uploads/2015/07/DrJayClinicalExperience.pdf>. Accessed September 29, 2016.
24. DeMill SL, Granata JD, McAlister JE, Berlet GC, Hyer CF. Safety analysis of cryopreserved amniotic membrane/umbilical cord tissue in foot and ankle surgery: a consecutive case series of 124 patients. *Surg Technol Int*. 2014;25:257-261.
25. Warner M, Lasyone L. An open-label, single-center, retrospective study of cryopreserved amniotic membrane and umbilical cord tissue as an adjunct for foot and ankle surgery. *Surg Technol Int*. 2014;25:251-255.
26. Kitaoka HB, Alexander IJ, Adelaar RS, Nunley JA, Myerson MS, Sanders M. Clinical rating systems for the ankle-hindfoot, midfoot, hallux, and lesser toes. *Foot Ankle Int*. 1994;15(7):349-353.
27. Van Lieshout EM, De Boer AS, Meuffels DE, et al. American Orthopaedic Foot and Ankle Society (AOFAS) ankle-Hindfoot score: a study protocol for the translation and validation of the Dutch language version. *BMJ Open*. 2017;7(2):e012884.
28. Chou LB, Niu EL, Williams AA, et al. Postoperative pain after surgical treatment of ankle fractures: a prospective study. *JAAOS Global Res Rev*. 2018;2(9):1-6.
29. Riboh JC, Saltzman BM, Yanke AB, Cole BJ. Human amniotic membrane-derived products in sports medicine: basic science, early results, and potential clinical applications. *J Sports Med*. 2015;44(9):2425-2434.
30. Dolivo D, Xie P, Hou C, et al. A dehydrated, aseptically processed human amnion/chorion allograft accelerates healing in a delayed murine excisional wound model. *Exp Cell Res*. 2021;400(2):112512.
31. Schneider W, Jurenitsch S. Normative data for the American orthopedic foot and ankle society ankle-hindfoot, midfoot, hallux and lesser toes clinical rating system. *Int Orthop*. 2016;40(2):301-306.

**How to cite this article:** Tacktil JZ, Rasor Z, Adams J, et al. Wound repair, safety, and functional outcomes in reconstructive lower extremity foot and ankle surgery using a dehydrated amnion/chorion allograft membrane. *Int Wound J*. 2022;1-9. doi:10.1111/iwj.13809